

Consensus of the 3rd Round Table Barcelona June 2013

Mark Rogers FRCS (Tr & Orth)

Derek Park FRCS (Tr & Orth)

Dishan Singh FRCS (Orth)



Aspects of Orthopaedic Foot & Ankle Surgery

Preface

The 1st Round Table meeting was held in Padua in June 2011, followed by the 2nd Round Table meeting in Paris in June 2012. The 3rd Round Table in Barcelona in June 2013 has once again followed a format where all attendees review the literature and present their individual experience on a topic with ample time for an informal discussion of the subject. There is no distinction between faculty and delegates.

Mark Rogers and Derek Park were responsible for recording opinions and capturing the essence of the debates, many of which resulted in consensus being reached on areas of foot and ankle practice. This booklet collates the literature review and the views of all those who participated. The opinions on consent, particularly, will hopefully guide practice and form the basis for a wider discussion at BOFAS.

This booklet does not represent Level 1 evidence derived from prospective randomized controlled trials but represents the compilation of anecdotal reports and small case studies based on the combined experience of 34 British orthopaedic surgeons as well as Judith Baumhauer from the USA and Harvinder Bedi from Australia.

I hope that you will find something of use and relevant to your own practice.

Dishan Singh, MBChB, FRCS, FRCS (Orth)

Consultant Orthopaedic Surgeon

Royal National Orthopaedic Hospital

Stanmore, UK

Consensus of the 3rd Round Table

Barcelona 2013

Mark Rogers

Derek Park

Dishan Singh



Aspects of Orthopaedic Foot & Ankle Surgery

1. Consent in Foot & Ankle Surgery
2. Peroneal Tendon Disorders
3. Management of the Mangled Foot
4. Ankle Instability
5. Gastrocnemius Tightness

Convenors:

Mr Dishan Singh

Mr Paul Cooke

Mr Nick Geary

Mr Fred Robinson

Hosts:

Ortho Solutions

Distilled in this document are the thoughts and opinions with consensus where possible of 30 Orthopaedic Foot and Ankle Consultant Surgeons who gathered from across the United Kingdom, USA and Australia. Though eminence rather than true evidenced based medicine this represents the concepts of over 200 years of combined experience. A basis of invited lectures introduced open and frank discussion from which consensus was sought. The statements herein only represent those of individuals and no claim is made that they are irrefutable. All the percentage figures quoted represent the proportion of the surgeons present who voted on the subject in discussion.

Consensus Session 1: Consent in Foot & Ankle Surgery

Chairman: Paul Cooke

The session explored several areas of the consent process including attitudes toward the consent process, practical issues of how and when consent should be taken and evidence used to inform patients of risks and benefits when taking consent.

Introduction: Paul Cooke

For consent to be valid the following essentials must be met:

- The patient must be competent to give consent
- They must have received sufficient information to make their decision
- They must not be acting under duress (including time duress, and hence the rationale of the DOH recommendation for consent to be taken in advance of surgery ie in clinic or pre-assessment clinic)

The surgeon should mention any significant risk that would affect the decision of a reasonable patient.

Misconceptions in consent:

- The 1% rule is law
- Listing a complication on the consent form relieves you of the responsibility to avoid it
- Listing a complication on the consent form is evidence that it has been discussed

Questions regarding current consent practice:

1. Do you ask the patient to sign the consent form in advance of the day of surgery?

Always	8	27%
Usually	14	47%
Sometimes	4	13%
Never	4	13%

2. Is the person taking consent capable of performing the procedure?

Always	12	40%
Usually	16	53%
Sometimes	2	7%
Never	0	0%

3. Do you discuss the option of doing nothing?

Always	23	77%
Usually	7	23%
Sometimes	0	0%
Never	0	0%

4. Do you provide written material to support the consent process?

Always	4	14%
Usually	10	36%
Sometimes	11	40%
Never	3	10%

There was broad agreement among delegates that patients undergoing inpatient surgery should be consented in advance of their admission, in some form of pre-assessment or consent clinic. There are inevitably local variations between Trusts as to how this is implemented, with some surgeons not having routine access to a pre-assessment clinic: only 17/30 (57%) of the delegates have a regular "pre-assessment" clinic, of which only 12 (40%) were "consultant led".

A further interesting question was raised during the discussion: *Should we take consent for low complexity day case procedures, eg bunion surgery, at the outpatient consultation (ie when the patient is listed for surgery)?* These patients may have no medical need to attend a "pre-assessment" clinic and we are being advised by the DoH guidelines to consent them in advance of their attendance for surgery. One response might be that all patients should come to a consent clinic but this may be needlessly burdensome and costly. Another solution would be to allocate more time to outpatient slots to potentially consent day case patients when they are listed for surgery. There was concern expressed that this may "pressurise" patients to sign a consent form on a first clinic attendance and there would be a need to increase time allocations to clinic slots, reducing throughput.

Question: How much extra time would you allocate to an outpatient attendance to consent a patient for bunion surgery?

<5 mins	0	
5-10 mins	28	93%
10-15 mins	2	7%
>15 mins	0	

Consent for Bunion Surgery - Mark Rogers

Remarkably for a common procedure such as hallux valgus correction, there is no current agreement on which complications that should be listed on the consent form for bunion surgery.

Consent practice for hallux valgus correction varies widely:

At the 2012 BOFAS meeting in Newport, 25 Foot and Ankle Consultants were asked to complete a questionnaire which aimed to determine which complications of surgery were routinely written on the consent form. The form offered 22 possible surgical complications and respondents were asked to indicate which complications they would “always”, “sometimes”, “never” or “never but should” include on the consent form for a hallux valgus correction.

The number of complications “always” listed for bunion surgery varied between 4 and 18, with a mean of 12. Table 1 shows the possible response options and their relative frequency of inclusion on the consent form by the 25 respondents. The only possible complication recorded by all respondents was infection.

The speaker presented his personal view and practice of hallux valgus consent:

Recurrence, hallux varus and transfer metatarsalgia are all distinct complications that the surgeon has a degree of control over and hence should be mentioned by name.

There is wide variability in the use of several terms that cover nerve injury: numbness, sensitivity, hyperaesthesia, CRPS etc. It is not clear what is meant by “CRPS” and doubtful whether a patient or even surgeon could satisfactorily explain it. The speaker uses the term “numbness including painful numbness” which he feels covers both anaesthetic skin from the division of cutaneous nerves and also the hypersensitivity and pain that may be part of a pain syndrome. His view was that patients may understand this term better.

The use of the term “dissatisfaction” covers individual issues, discussed during the consent process regarding the return to activity and daily living following surgery and whilst surgically a stable well aligned foot will have been achieved, the patient may still require the use of an orthosis or be unable to wear fashion shoes.

The speaker now discusses the following when consenting patients for hallux valgus correction:

Infection

DVT/PE

Recurrence

Hallux Varus

Transfer Metatarsalgia

Dissatisfaction

Stiffness

Numbness Including Painful Numbness

Further surgery

Ongoing Pain

Table 1. Results of Survey of Consent Practice of 25 Consultant Foot and Ankle Surgeons, surveyed at BOFAS Newport Meeting, 2012.

COMPLICATION	ALWAYS	SOMETIMES	NEVER	NEVER BUT SHOULD!
Infection	25	0	0	0
Recurrence	22	0	2	1
Numbness	21	0	4	0
Stiffness	17	2	6	0
Pain	17	2	6	0
Failure	15	3	7	0
DVT/PE	15	3	6	1
Swelling	13	4	8	0
Dissatisfaction	13	3	8	1
Hyperaesthesia/sensitivity	13	6	5	1
Further surgery	13	2	10	0
Non union/delayed union	12	6	7	0
Malunion	10	4	10	1
Scar	9	2	14	0
Bleeding	8	3	12	2
Hallux varus	6	5	12	2
Transfer metatarsalgia	6	8	9	2
Complex Regional Pain Syndrome	5	6	12	2
Removal of Metalwork	5	10	9	1
Risk of anaesthesia	5	0	18	2
Risk of amputation	1	0	21	3
Death	0	0	24	1

Discussion

There was broad agreement that the term CRPS was potentially unhelpful as the condition is poorly understood. However there is a need to make reference to a post-operative condition of pain, swelling and or numbness that could be interpreted as a pain syndrome.

The question was raised of whether the risk of amputation should be discussed with the patient. Several delegates were of the opinion that if an elective uncomplicated bunion correction subsequently resulted in amputation, there would likely be other flaws in the patient's care that would be of more importance than whether the risk of amputation was discussed or not.

Question: In the case of an uncomplicated bunion correction in a patient under the age of 70 years, would you consent the patient for the risk of amputation?

Yes	1	(3%)
No	29	(97%)

Consent for Ankle Arthroscopy - Paul Hodgson

Adverse outcome following ankle arthroscopy (and indeed any surgery) could be thought of under 3 headings:

1. Side effects: pain, swelling , stiffness
2. Failure to achieve the desired aim
3. Complications.

A meta-analysis (Zengerink M, Van Dijk C. Complications in ankle arthroscopy. Knee Surg Sports Traumatol Arthrosc 2012;0:1420-31) listed the complications of ankle arthroscopy. The most common complication was nerve injury, average 3.7% (1-27%). Most are transient and resolve in 1 year. The risk will be dependent upon the portal used, but the intermediate branch of the superficial peroneal nerve is that which is most commonly reported as injured via the anterolateral portal.

Nerve injury	3.7% (1-27%)
Infection	
Superficial	1.6% (0-8%)
Deep	0.6% (0-3%)
CRPS	0.3% (0-2%)
Instrument breakage	0.3% (0-2%)
Sinus/delayed healing	0.9% (0-4%)
DVT/PE	<1%
Haemarthrosis	<1%

Consent for Ankle Fusion - Raman Dega

The message that consent is a process was re-iterated. This begins in the clinic and continues through the pre-assessment clinic and onto the ward on the day of operation. An interesting analogy was raised that consent is a "ritual" and as with many rituals there may be disagreement about its conduct.

Consent may be thought of as having objectives/aims for both patient and surgeon: The patient must be given adequate information about their condition such that they can understand it and make an informed choice between treatment options. Risks and benefits of these choices must be discussed and the patient be given realistic expectations of outcome. Specifically with ankle arthritis, a discussion about the role and indication for ankle replacement as an alternative to fusion must be discussed.

For this process to be effective, the surgeon must have adequate knowledge to inform the patient as well as be able to discuss facts about outcome, including chances of success or failure.

The decision of when to operate and the merit in exhausting available non-operative measures is important to consider and well as deciding on a reason to operate.

Risks were presented as general (infection, DVT/PE, CRPS, risk of anaesthesia) and specific (nerve injury, non-union, malunion).

Several papers are useful as a basis for informing patients about the outcome of ankle fusion:

1. Myerson et al. Ankle Arthrodesis vs TTC Arthrodesis. Patient outcomes, satisfaction and return to activity. *Foot Ankle Int* 2013;34:636-4
Fusion achieves good functional outcomes and satisfaction. Certain activities become more difficult following fusion such as tennis and soccer but some activities are improved: driving, walking, golf.
2. Van Dijk et al. Medium to long term outcome of ankle arthrodesis. *Foot Ankle Int* 2011;32:940-47.
At a mean follow up 9 years, a satisfaction rate of 90% was reported. Union was achieved in 91% of patients. There was a 1% infection rate.
3. Trichard T et al. Long term behaviour of ankle fusion: assessment of the same series at 7 and 23 year follow up. *Rev Chir Orthop Reparatrice Appar Mot* 2006;92:701-07
Half of 52 patients were lost to follow up at 23 years however there was little clinical expression of hindfoot arthritis in the triple complex of remaining patients although there is radiographic deterioration of these joints.
4. Soohoo et al. Comparison of reoperation rates following ankle arthrodesis and total ankle arthroplasty. *Journal Bone Joint Surg (Am)* 2007;89:2143-49
TAR showed 9% revision surgery rates at 1 year and 23% at 5 years, compared to ankle fusion group where revision rates were 5% at 1 year and 11% at 5 years.

Consent for Ankle Fracture Fixation - AI Best

There are numerous small studies on outcome of ankle fractures that may inform the consent process, but two notable large data base studies are by Soohoo¹ and Koval². Between them they represent the outcome of approximately 90,000 patients. The series of Soohoo is broadly representative of UK practice as a whole, whilst that of Koval, with a mean patient age of 76 years, represents outcome of ankle fracture in the elderly.

The 90 day complication rates of **all** ankle fractures are as follows:

Infection (deep)	1.44% (1.4-6.8%)
PE (DVT)	0.34% (0.12-2.7%)
Re-fixation	0.82%
Amputation	0.16%
Mortality	0.37-1.37%
Nerve injury	3.8-20% (note a 10% incidence even in nonoperative group)
Non union	<1%
Arthrodesis	0.96% at 5 years

There are specific patient groups in which certain complication rates are higher:

1. Complicated diabetics (ie those with evidence of complications of diabetes: neuropathy, retinopathy, nephropathy etc).

Infection	7.7-19%
Amputation	3.86%
Arthrodesis	4.86% at 5 years

2. Peripheral vascular disease

Infection	6.8%
Amputation	3.4%

3. The elderly (Age over 75 years)

Infection	2.37%
Amputation	0.9%
Mortality	4.91-6.7% at 90 days to 1 year
Metalwork removal	11-18%

4. Smokers (greater than 5 cigarettes per day)

This confers a wound infection rate approximately 5 times higher than in non-smokers.

It is reasonable to conclude that a closed ankle fracture in a young healthy patient will have low rates of complication, but that there are specific patient groups highlighted above in which ankle fracture is not a benign injury.

References

1. SooHoo NF, Krenek L, Eagan MJ, Gurbani B, Ko CY, Zingmond DS. Complication rates following open reduction and internal fixation of ankle fractures. *J Bone Joint Surg Am.* 2009;91:1042-49
2. Koval KJ, Zhou W, Sparks MJ, Cantu RV, Hecht P, Lurie J. Complications after ankle fracture in elderly patients. *Foot Ankle Int* 2007;12:1249-55

Consensus Session 2: Peroneal Tendon Disorders

Chairman: Fred Robinson

Peroneal Tendon Tears - Alex Wee

The clinical history to suggest a diagnosis of peroneal tendon disorder may be relatively short: a twisting injury in an athlete or an alteration in training regime or running style may precipitate a peroneal tendon injury.

The presentation of a tendinopathic pathology may be more insidious. The patient may complain of swelling, pain, crepitus or a clicking/flicking sensation behind the lateral malleolus. There may be an associated history of ankle instability.

Asking the patient to localise the pain with one finger may be beneficial, as the specific localisation of pain may be indicative of the pathology and help to clinically rule out differential diagnoses such as pain from the subtalar joint or ankle.

Examination findings specific to the peroneal tendon disorder are swelling, elicited pain on direct palpation or passive stretch in the presence of synovitis, and the replication of tendon subluxation by ankle dorsiflexion and eversion.

Other features of the foot and ankle examination are also important - such as hindfoot alignment, noting the presence of a cavus foot, assessment of ankle stability etc as these may point to other pathologies or the aetiology of the peroneal pathology.

Several differing radiological modalities may be employed to confirm the diagnosis:

Ultrasound by a skilled musculoskeletal radiologist¹ has been shown to be highly sensitive (100%), specific (85%) and accurate (90%). It has the advantages of a dynamic investigation, allows demonstration of subluxation and guides simultaneous injection if indicated.

MRI is useful if the pain around the ankle is more global or if multiple pathologies are suspected (ankle instability, chondral injury etc) and as such may confirm or refute differential diagnoses such as intra-articular pathology of the ankle and subtalar joint. The sensitivity and specificity of MRI for peroneal tendon pathology is lower than that of US² with reported sensitivity of 83% and specificity of 75%.

Peroneal tendon tears have been classified by Brandes³ into anatomical zones, by Sobel⁴ according to the size and extent of the tear and by Brodsky⁵ into those tears involving either less than or more than 50% of the tendon substance.

Management

A trial of non-operative management should be employed and encompass activity modification, analgesia, immobilisation with a boot in the acute period, an orthotic incorporating a lateral

hindfoot wedge and an explanation to the patient that the majority of cases will respond to non-operative management with an expected recovery of several months.

Surgical intervention may be considered in those who fail non-operative treatment. Importantly the complications of open peroneal tendon surgery are not rare. Although publications are typically small retrospective case series, it is notable that Redfern and Myerson⁶ demonstrated 9/28 patients with complications of infection, neuritis, CRPS symptoms, adhesions and wound healing problems.

However the small series in the literature do report reasonable results with Myerson's paper⁶ demonstrating 91% of patients regaining moderate to full peroneal tendon strength and post op AOFAS scores of 82 being representative.

Open surgery involves tendon debridement, tear excision or repair, tubularisation and repair of the retinaculum. A figure of 50 % or more of dysfunctional tendon (based on Brodsky's classification) is taken as indicating the need for tenodesis. In the context of two dysfunctional tendons, there may be a role for FDL/FHL single stage transfer⁷.

References

1. Grant TH, Kelikian AS, Jereb SE, McCarthy RJ. Ultrasound diagnosis of peroneal tendon tears. A surgical correlation. J Bone Joint Surg Am 2005;87:1788-94
2. Lamm BM, Myers DT, Dombek M, Mendicino RW, Catanzariti AR, Saltrick K. Magnetic resonance imaging and surgical correlation of peroneus brevis tears. J Foot Ankle Surg 2004;43:30-6
3. Brandes CB, Smith RW. Characterization of patients with primary peroneus longus tendonopathy: a review of twenty two cases. Foot Ankle Int 2000;21:462-68
4. Sobel M, Geppert MJ, Olson EJ, Bohne WH, Arnoczky SP. The dynamics of peroneus brevis tendon splits: a proposed mechanism, technique of diagnosis and classification of injury. Foot Ankle 1992;13:413-22
5. Krause JO, Brodsky JW. Peroneus brevis tendon tears: pathophysiology, surgical reconstruction and clinical results. Foot Ankle In. 1998;19:271-9
6. Redfern D, Myerson M. The management of concomitant tears of the peroneus longus and brevis tendons. Foot Ankle Int 2004;25:695-707
7. Jockel JR, Brodsky JW. Single stage flexor tendon transfer for the treatment of severe concomitant Peroneus Longus and Brevis tendon tears. Foot Ankle Int 2013;34:666-72

Peroneal Tendon Subluxation and Groove Deepening - Maneesh Bhatia

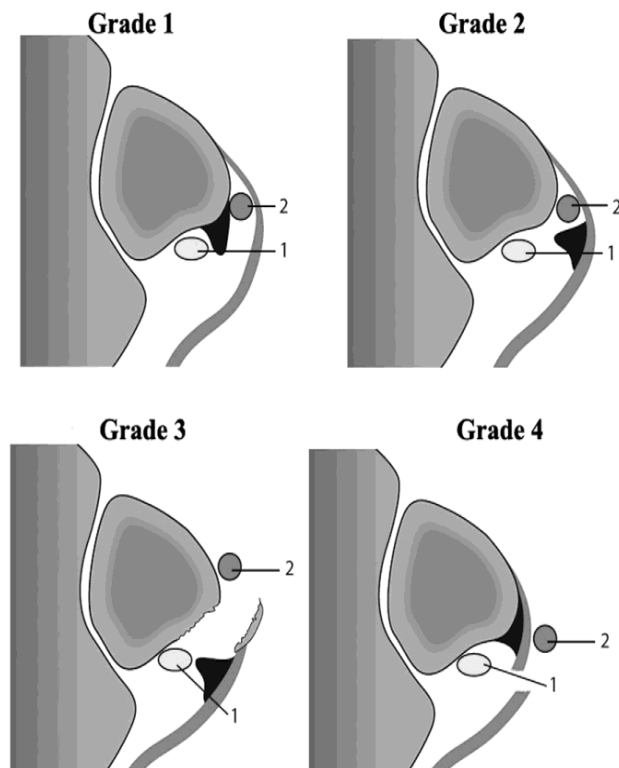
The peroneal tendons lie in a triangular shaped fibro-osseous tunnel formed by the fibula anteriorly, the superior peroneal retinaculum and fibrocartilagenous lip laterally and the talo-fibular and calcaneo-fibular ligaments medially.

The posterior surface of the fibula is typically concave but there is anatomical variation. Edwards¹ demonstrated a flat or even convex posterior surface to the fibula in 18% of cases.

Peroneal tendon subluxation is uncommon. Acute traumatic dislocation may occur in forced dorsiflexion injuries of the ankle with violent peroneal contraction. Whilst it may occur in isolation, it can be associated with ankle instability or hindfoot varus.

Patients typically report hearing a “pop” or “snap” acutely subsequently followed by pain and swelling. They may report a subsequent feeling of “flicking” with certain activities or positions of the ankle. The diagnosis may be confirmed with USS and classified according to Oden² as below.

Raikin³ further described an “intra-sheath” type of subluxation subdivided into type A (P. Longus and Brevis flicking over each other within the sheath) and type B (P longus herniating through a tear in brevis).



Oden's Classification of peroneal tendon tears. Peroneus Brevis (1), Peroneus Longus (2).

Non operative management with casting has been described but carries failure rates of up to 75%.

Several procedures have been described to treat peroneal tendon subluxation including groove deepening procedures⁴, bone block advancement procedures⁵ and rerouting the tendons behind the calcaneo-fibular ligament⁶.

Deepening of the peroneal groove is most popular and may be achieved through direct or indirect methods.

Direct groove deepening involves osteotomising the distal fibula and elevating an intact cortical hinge of bone to allow curettage of the underlying cancellous bone to deepen the groove.

Indirect deepening is achieved by sequential passes of increasing drill diameters in the longitudinal axis of the distal fibula before “tamping down” the posterior cortex.

The literature records several small case series of outcome following a variety of procedures⁴⁻⁶ all of which have been reported as successful.

References

1. Edwards M. The relation of the peroneal tendons to the fibula, calcaneus and cuboideum. *Am J Anat* 1927;42:213-252
2. Oden RR. Tendon injuries about the ankle resulting from skiing. *Clin Orthop Rel Res* 1987;(216):63-9
3. Raikin SM, Elias I, Nazarian LN. Intrasheath subluxation of the peroneal tendons. *Journal Bone Joint Surg Am* 2008;90:992-9
4. Mendicino RW, Orsini RC, Whitman SE, Catanzariti AR. Fibula groove deepening for recurrent peroneal subluxation. *J Foot Ankle Surg* 2001;40:252-63
5. Micheli LJ, Waters PM, Sanders DP. Sliding fibula graft repair for chronic dislocation of the peroneal tendons. *Am J Sports Med* 1989;17:68-71
6. Boykin RE, Ogunseinde B, McFeely ED, Nasreddine A, Kocher MS. Preliminary results of calcaneo-fibular ligament transfer for recurrent peroneal subluxation in children and adolescents. *J Pediatr Orthop* 2010;30:899-903

Peroneus Quartus – Dishan Singh

Peroneus quartus is an accessory muscle of the lateral compartment of the leg. It has been shown to be present in between 6%¹ and 22% of individuals².

It may originate from the peroneus brevis or longus muscles or the surface of the fibula and insert variably into the retrotrochlear eminence, base of 5th metatarsal or cuboid.

Associated pathology includes longitudinal tears of the peroneus brevis, peroneal tendon subluxation or a prominent retrotrochlear eminence.

It must not be misinterpreted on imaging of the ankle as a split in the adjacent peroneal tendons.

If seen at operation, it should be excised to reduce the volume of the contents of the peroneal compartment.

References

1. Zammit J, Singh D. The peroneus quartus muscle. Anatomy and clinical relevance. J Bone Joint Surg Br 2003;85:1134-7
2. Sobel M, Levy ME, Bohne WH. Congenital variations of the peroneus quartus muscle: an anatomic study. Foot Ankle 1990;11:81-9

Discussion

The role of injection for peroneal tendon disorder provoked extensive debate. There was discussion of the detrimental effect of both steroid and local anaesthetic to the collagen structure of tendon.

There was broad agreement that if steroid injections were to be administered within the peroneal sheath, then they should be of low dose steroid, using a high volume of local anaesthetic and ensuring the injection was in the sheath and not intra-substance to the tendon as demonstrated by the lack of resistance to injection.

13 delegates reported having seen a rupture of the peroneal tendons after an injection.

Concerning current practice:

1. 3 (10%) would inject "blindly" in a clinic setting with no radiological guidance
2. 17 (59%) would inject under ultrasound guidance
3. 9 (31%) would never inject around the peroneal tendons (for reasons of concern regarding potential rupture)

However, no member thought it negligent to inject around the peroneal tendons.

Concerning the indication for injection:

1. 20 (62%) would offer injection for an intact tendon with tenosynovitis
2. 12 (38%) would inject in cases of partial tear of a peroneal tendon
3. No member would inject in cases of a tendon tear and subluxation

8 members would immobilise a patient following peroneal tendon sheath injection with a walking boot.

With regard to surgical intervention:

1. Only 2 members routinely repair any tear at surgery, irrespective of its size.
2. 23 members use the "50% rule" based on Brodsky's classification and tenodes the Brevis and Longus if more than 50% of a tendon was felt to be degenerate.
3. There was 100% agreement that a prominent peroneal tubercle should be debulked.

Painful Os Peroneum - Senthil Kumar

Present in up to 30% of individuals¹, the Os Peroneum represents a sesamoid bone of the Peroneus longus. It may be unipartite or bipartite, articulates with the cuboid and calcaneus and may have multiple fibrous attachments to calcaneus, base of 5th metatarsal and the adjacent peroneus brevis.

As such, it is thought to be comparatively “tethered” compared to other sesamoid bones and therefore be subjected to greater stress, perhaps explaining the aetiology of injury.

The symptomatically painful Os Peroneum is rare: the literature containing only case reports describing its presentation and treatment.

Sobel², in 1994, coined the phrase “Painful Os Peroneum Syndrome” (POPS) but this term is also used to include disorders of the peroneus longus.

Injury to the os peroneum may be acute ie a fracture through a unipartite os or a diastasis of a bipartite os. In the acute setting, it is important to note that the function of peroneus longus is lost.

Chronic repetitive sprain type injuries do occur but here the function of the peroneus longus is preserved, perhaps because the brevis has compensated for the loss of function.

Presentation may be with pain and swelling over the lateral border of the foot and in the chronic setting, there may be a history of recurrent “giving way”. A high index of suspicion is required.

Investigations may include plain radiography, USS or MRI, all of which may be diagnostic.

In the acute setting management may be conservative with a below knee cast or walking boot, as the displacement between fragments may not be excessive.

If presentation is greater than a month from injury, then operative intervention (fixation or excision of the fragment and tendon repair) is probably indicated.

References

1. Muehleman C, Williams J, Bareither ML. A radiologic and histologic study of the os peroneum: prevalence, morphology and relationship to degenerative joint disease of the foot and ankle in a cadaveric sample. Clin Anat 2009;22:747-54
2. Sobel M, Pavlov H, Geppert MJ, Thompson FM, DiCarlo EF, Davis WH. Painful os peroneum syndrome: a spectrum of conditions responsible for plantar lateral foot pain. Foot Ankle Int 1994;15:112-24

Cuboid Syndrome - Ioan Jones

This syndrome describes a rather non-specific pain localised to the lateral border of the hindfoot, over the calcaneo-cuboid joint or bases of the 4th and 5th metatarsals. It is referred to in the literature under a variety of names, including a “dropped cuboid”, “locked cuboid”, “peroneal cuboid syndrome” and “subluxed cuboid”.

It is felt to be due to a subtle instability of the calcaneo-cuboid joint with a traumatic aetiology but this is debated. There is also thought to be an association with instability of the first ray which may cause excessive mechanical loading of the lateral column in midstance to toe off of the gait cycle. It is typically a diagnosis of exclusion and radiological investigations including MRI are normal.

The diagnosis may be confirmed by a positive diagnostic response to local anaesthetic/steroid injection to the calcaneo-cuboid joint.

Management is non-operative with orthotics.

Question and Discussion

How many delegates believe in the entity of cuboid syndrome?

YES: 18/30 (60%)

NO: 12/30 (40%)

Although there was no consensus that cuboid tunnel syndrome exists with a discrete aetiology of instability at the calcaneo-cuboid joint, there was broad agreement that there does exist a syndrome of "lateral foot pain" in patients in whom radiological investigations are normal.

The aetiology of the pain was debated as being either neurogenic, synovitic, mechanical/instability, or from adhesive capsulitis. There was a proposal that the lateral foot pain was secondary to instability of the medial column and overload of the lateral rays.

No consensus could be reached during this debate.

The Cavo-Varus Foot and Peroneal Tendons - Fred Robinson

A cavo-varus foot position may cause overloading of the peroneal tendons during activity causing tendonosis and tears, particularly of the peroneal longus tendon. Therefore, when assessing the patient with peroneal tendon pathology, care should be taken to assess the foot shape and in particular hindfoot alignment.

There is certainly an association between hindfoot varus and lateral ligament injury of the ankle and Strauss¹ demonstrated that 24% of failed lateral ankle ligament reconstructions were in varus aligned heels that had not been corrected. Similarly, there is an association between lateral ligament instability and varus ankle arthritis and although there is a long latency time of 34 years², correcting the hindfoot alignment halts the progression toward arthritis.

Little attention is given in the literature regarding the management of peroneal tendon pathology in the context of a varus hindfoot, other than descriptions of bony procedure to correct the foot shape.

Discussion centred around simultaneous peroneal tendon exploration and repair at the time of cavo-varus foot correction. The argument that correcting the shape of the foot defunctions the peroneal tendons and hence negates the need to reconstruct them was presented. No consensus was reached.

References

1. Strauss JE, Frosberg JA, Lippert FG3rd. chronic lateral ankle instability and associated conditions: a rationale for treatment. Foot Ankle Int 2007;28:1041-44
2. Valderrabano V, Hintermann B, Horisberger M, Fung TS. Ligamentous posttraumatic ankle osteoarthritis. Am J Sports Med 2006;34:612-20

Consensus Session 3: Management of the Mangled Foot

Chairman: Fred Robinson

The mangled foot - Rick Brown and Simon Clint

The mangled foot as defined by a foot sustaining a substantial mechanism of injury, with multiple fractures, and potential soft tissue compromise is thankfully rare in the UK.

The experience of a busy district general hospital was presented. Thirteen injuries were treated in the preceding year equating to an incidence of 1.8/100,000 population per year. The mechanism of injury is typically industrial, agricultural, road traffic accidents or falls from height.

Predicting the outcome of such injuries is difficult and in the most severe cases the difficult decision of salvage and reconstruction versus acute amputation presents itself.

In 1990, the Mangled Extremity Severity Score¹ (MESS) was published. Based on the four parameters of the energy involved in the injury, the limb ischaemia time, the degree of shock and the age of the patient, it attempts to predict the outcome of such injury and to guide decision making on the likely success of salvage of such injuries. The authors demonstrated a high MESS score was indicative of the need for amputation. However, the experience of the US Army over the last 10-15 years from the conflicts in the Gulf and Afghanistan has shown the MESS score to be unreliable for the prediction of limb salvage or amputation².

The US Army experience would also suggest that the outcome of a delayed amputation is likely to be as good as a primary "acute" amputation but the key to their success probably lies in the benefit conferred by intensive rehabilitation programmes².

The "civilian" experience of the mangled foot and ankle was published earlier this year³. The LEAP (Lower Extremity Assessment Project) study included 174 feet with severe open hindfoot or ankle injuries, treated by salvage or by immediate amputation.

The principal measure of outcome was the Sickness Impact Profile. When compared to patients treated with below knee amputation, salvage patients who had required free flaps and/or ankle arthrodesis had significantly worse 2 year outcomes.

The UK experience of open foot fractures has been published by Court-Brown and McQueen⁴. 348 open foot fractures were treated at their institution in the preceding 23 years. They identified 3 severity levels if injury:

Level 1: isolated open fractures of the forefoot

Level 2: multiple open forefoot fractures

Level 3: open fractures of the midfoot and hindfoot.

Open fractures of the calcaneus, talus and midfoot conferred amputation rates of 16.6%, 18.2% and 30% respectively.

!3.3% of patients with open multiple metatarsal fractures underwent forefoot amputation.

Management of the soft tissues in severe foot injury

The principals of management of open fractures of the foot and ankle are summarised in the joint publication from the British Orthopaedic Association (BOA) and British Association of Plastic, Reconstructive and Aesthetic Surgeons, available to download on from the BOA website⁵.

These guidelines emphasise the challenging nature of these injuries, the need for definitive internal fixation with soft tissue coverage if possible and the consideration of primary amputation in severe injuries.

1. Helfet D, Howey T, Sanders R, Johansen K. Limb salvage versus amputation. Preliminary results of the Mangled Extremity Severity Score. Clin Orthop Rel Res 1990;56:80-6
2. Shawen SB, Keeling JJ, Branstetter J, Kirk KL, Ficke JR. The mangled foot and leg: salvage versus amputation. Foot Ankle Clin 2010;15:63-75
3. Ellington JK, Bosse MJ, Castillo RC, MacKenzie EJ. The mangled foot and ankle: results from a 2-year prospective study. J Orthop Trauma 2013;27:43-8
4. Court-Brown C, Honeyman C, Bugler K, McQueen M. The spectrum of open fractures of the foot in adults. Foot Ankle Int 2013;34:323-28.
5. Standards for the management of open fractures of the lower limb. Downloadable at <http://www.boa.ac.uk/Publications/Documents/Lower%20Limb%20Guide.pdf>

Compartment Syndrome of the Foot

Compartment syndrome is estimated to occur in approximately 6% of cases of foot and ankle trauma compared to 1.6% of tibial fractures.

The literature regarding the diagnosis, treatment and outcome is scarce but historically there has been a drive toward prompt decompression with open fasciotomies through a variety of surgical approaches.^{1,2}

The volume of literature on the outcome of foot fasciotomy is minimal and based on low numbers of patients. Anecdotally, the outcome following fasciotomy is poor and Myerson² has shown appreciable limitation of function in patients who have had fasciotomies.

The vast majority of the evidence for fasciotomy has been extrapolated from data regarding tibial fractures.

There is genuine concern regarding converting a closed foot injury to an open one with fasciotomies and infection rates in the foot following fasciotomy may be high.

References

1. Myerson M. Acute compartment syndromes of the foot. Bull Hosp Jt Dis Orthop Inst 1987;47:251-6.
2. Myerson M. Management of compartment syndromes of the foot. Clin Orthop Rel Res 1991;271:239-48.

Consensus discussion and voting

12/30 delegates regularly undertook foot and ankle trauma surgery.

8/30 delegates work in a major trauma centre.

3/30 (10%) had performed a fasciotomy of the foot in the preceding year.

12/30 (40%) had performed below knee amputation for trauma in the preceding year.

3/30 (10%) of delegates would base the decision for fasciotomy on a pressure reading alone.

11/30 (33%) would base their decision for fasciotomy on clinical grounds (pain, swelling).

20/30 (67%) delegates have seen patients made worse by foot compartment decompression.

Discussion focused on why the outcome of foot fasciotomy was so much worse than that in the lower limb for tibial fractures. There was agreement that the fracture patterns, nature of injury and soft tissue injury to the foot was not comparable to that of a tibial fracture.

The consequences of NOT performing lower limb fasciotomy for tibial fracture would result in the significant sequelae of neurovascular compromise and muscle contracture which carries significant morbidity.

In the foot, the sensory nerves are outside the fascial envelope so sensory loss is less and the limitation to function posed by clawed toes is much less than that of a Volkmann's contracture of the calf.

There was agreement that the risk of NOT doing something in the foot is not as great as the risk of NOT doing something in the leg whilst the dangers are higher.

Questions:

In a patient with clinical signs and symptoms of a foot compartment syndrome or one in whom elevated compartment pressures are measured, who thinks it is mandatory to perform fasciotomy?

Yes: 3 (10%)

No: 27 (90%)

Who thinks measuring the compartment pressure in a foot with potential compartment syndrome is mandatory?

Yes: 0 (0%)

No: 30 (100%)

The Establishment Of The Trauma Network And Its Impact On Foot And Ankle Trauma.

By the turn of this century it was apparent that trauma care in the UK was lagging behind that in North America and other parts of Europe and a series of reports from the BOA, Royal College of Surgeons, CEPD and the National Audit Office all pointed to the quality of trauma care in the UK being variable and too often poorly performed.

In April 2009, Keith Willet was appointed as "Trauma Tsar" with the subsequent establishment of trauma networks throughout the UK, going "live" in April 2012. The network is based around regional centres, the Major Trauma Centres, supported by local Trauma units. The function of the network is to ensure that appropriate patients go to the MTC but that just as quickly patients may return to their local trauma units for ongoing care and rehabilitation.

Which patients should go to the MTC? The Clinical Advisory Group concluded those with an Injury Severity Score(ISS) >16 are appropriate for transfer, but the ISS can only be calculated retrospectively.

The paramedics now use a triage tool based on suspected injury and physiological parameters, designed to slightly over triage patients. Therefore, ideally all patients identified as "major trauma" patients should go to the MTC as long as they can be transferred safely within 45 minutes have an airway and not be at risk of exsanguination.

Criteria now used to triage patients to the MTC include:

Open pneumothorax

Crushed, de-gloved or mangled limb, proximal to the ankle or wrist

Suspected major pelvic fracture

Neck or back injury with paralysis

How does this affect foot and ankle trauma provision?

The average ISS for patients in McQueen’s paper was 5. The vast majority of foot and ankle trauma is seen in isolation and not part of the polytrauma patient.

Has the establishment of the trauma network changed the pattern of foot and ankle trauma seen in the local trauma units?

The Cheltenham and Gloucester experience was presented. A review of trauma patients with foot and ankle injuries for a year pre and post introduction of the Trauma Network was presented.

No significant difference was reported in the percentage of open ankle fractures treated, the percentage of patients requiring external fixation of the foot and ankle, or the number of severe open ankle injuries that required subsequent input from plastic surgery in the year following the introduction of the Trauma Network.

Similarly, a review of all patients who were transferred to the regional MTC (Frenchay Hospital) from **all** the local trauma units who had a co-existent foot and ankle injury as part of their injury profile, demonstrated that the vast majority of transferred patients had multiple injuries and/or open fractures that required plastic surgical support.

Therefore in conclusion, the majority of severe foot and ankle trauma was managed by the local trauma units, the Trauma Network has had no significant impact on the numbers of patients with foot and ankle trauma presenting to the local units and hence the local Trauma units need to be staffed with Foot and Ankle surgeons to provide foot and ankle trauma care locally.

Questions

The questions explored what to do when significant foot and ankle trauma is admitted to your unit and a non foot and ankle specialist is on call:

1. What advice would you give to a **non** foot and ankle surgeon who has admitted a 44 year old man with a closed but significantly displaced Lisfranc injury, but without skin “compromise”?

Rest, elevate, splint and ice (await availability of foot and ankle surgeon)	25 (84%)
Perform reduction and percutaneous fixation with K wires	4 (13%)
Apply an external fixator	1 (3%)
Perform a definitive fixation	0

2. What advice would you give in the same scenario if the skin was compromised?

Rest, elevate, splint and ice (await availability of foot and ankle surgeon)	0
Perform a closed reduction and fixation with burried K-wires or screw fixation	10 (33%)
Apply an external fixator	3 (10%)
Undecided on method of fixation (dependent upon individual experience) but in agreement of need to intervene surgically	17 (57%)

Medial and Lateral Column Trauma to the Foot -Chris Blundell and Mark Davies

The bones (of the foot) are aligned in two functional columns. The **lateral column** includes the calcaneus, cuboid, and fourth and fifth metatarsals. The **medial column** includes the talus, navicula, cuneiforms, and the first, second, and third metatarsals.¹ Dillwyn Evans made reference to the columns of the foot in his paper in 1961, but there is no description of this in Sarrafian's Foot & Ankle anatomy textbook.²

Until fairly recently most reports in the literature regarding midfoot trauma focused primarily on talar fractures, with authors advocating non-operative management with closed reduction and plaster cast treatment, and discussing triple fusion as a salvage technique.^{3,4} Main and Jowett in 1975 classified midfoot trauma according to the direction of deforming force. They described medial, longitudinal, lateral, plantar, or crush injuries of the foot but made no direct reference to columns of the foot.⁵

Kelikian later described the Lisfranc joint and three-column theory, dividing it into:

- Medial: medial cuneiform and 1st metatarsal
- Middle: middle and lateral cuneiforms, and 2nd & 3rd metatarsals
- Lateral: cuboid and 4th & 5th metatarsals

The emphasis moved to stabilisation of the medial and lateral columns, with either open reduction and internal fixation, open reduction and external fixation, or primary arthrodesis. There was certainly a move away from closed reduction and plaster cast immobilisation.⁶

The importance of the column theory of the foot grew, with Hansen emphasising the following key principles.⁷

- Avoidance of lateral column shortening,
- Restoration of the medial column,
- Reduction of the naviculocuneiform joint.

The cuboid and navicula are crucial in maintaining the integrity of the lateral and medial columns of the foot respectively. The cuneiforms also play an important role as the cornerstone of the transverse arch of the foot.⁸ Based on this review by Pinney and Sangeorzan, the following summary points were made:

Key points in managing trauma of the foot:

1. Obtain the correct diagnosis - use of CT scan
2. Maintain appropriate medial and lateral column length
3. Maintain appropriate relationship between forefoot and hindfoot
4. Preserve Talonavicular joint
5. Preserve Cuboid-4th metatarsal and Cuboid-5th metatarsal joints
6. Stable internal fixation for reduction, consider primary arthrodesis if necessary
7. Allow adequate time frame for soft tissue and bony healing

To achieve this:

1. Plate from talus to 1st metatarsal
2. Plate from calcaneum to 4th & 5th metatarsals
3. Remove metalwork, start physiotherapy
4. No role for external fixation

Klaue et al in a case series of various midfoot and hindfoot fractures alludes to column length and advocates surgical approaches that allow visualisation of the talonavicular and calcaneocuboid joints. In cuboid injuries, consider an AO distractor to restore column length. If the injury is too severe primary arthrodesis should be considered. In navicular fractures, some shortening may be accepted. Avoid bone block reconstruction that may result in inadvertent medial column lengthening. Ultimately the salvage procedure is a triple arthrodesis.⁹

Sword et al wrote about the importance of the navicula and cuboid in column length and the transverse arch. The talus is considered to be in the medial column. Bridging the talonavicular joint, and stabilising from the talus to the 1st metatarsal may be necessary to maintain medial column length.¹⁰

In terms of evidence for treatment of Lisfranc injuries, there are conflicting reports in the literature. Coetzee and Ly found that primary arthrodesis of ligamentous Lisfranc injuries appears to be better treated with primary fusion rather than ORIF.¹¹ Rammelt found that primary ORIF with anatomic reconstruction is better than salvage arthrodesis.¹² Henning et al found no real difference in outcomes between primary arthrodesis and ORIF.¹³ Coetzee et al, in a systematic review concluded that both primary arthrodesis & ORIF have satisfactory and equivalent results.¹⁴

In assessing medial column injuries, it is important to have a high index of suspicion as these injuries are easily missed. Associated injuries should be ruled out. A proper neurovascular assessment is important and soft tissues should be treated with respect, especially in crush injuries. True medial column only injuries are often stable, and tend to be crush injuries rather than high speed injuries. In these cases where the lateral column is intact, no external fixation is required and definitive surgery can be performed once the soft tissues settle.

The Sheffield philosophy:

Initial focus on soft tissues, allow time to settle with temporary back slab POP, elevation, cold flowtron boots, and VTE thromboprophylaxis. They have moved away from compartment fasciotomies for compartment syndrome of the foot.

The timing of surgery:

- SCAN – (SPAN) – PLAN: If soft tissues not severely compromised
- SPAN – SCAN – PLAN: If soft tissues at risk

The Sheffield approach:

- A la carte approach to foot trauma
- Direct (Topliss approach)
- Open exposure and reduction
- Simple external fixators to restore column length

- *Locking plates to span joints if necessary*
 - *Percutaneous reduction and sometimes percutaneous fixation, away from exposure*
- = Focusing on restoration of columnar length, with particular attention to the navicular**

Consensus statements for Management of the Mangled Foot

Discussion revolved around case presentations of complex midfoot and forefoot fractures and general management strategies. As each case was different, it was difficult to take away any general consensus statements.

There was a split of opinion that non-Foot & Ankle surgeons should apply an early external fixator in the absence of a Foot & Ankle surgeon.

References

1. Dumontier TA, Falicov A, Mosca V, Sangeorzan B. Calcaneal lengthening: investigation of deformity correction in a cadaver flatfoot model. *Foot Ankle Int* 2005;26:166-70.
2. Evans D. Relapsed club foot. *J Bone Joint Surg Br* 1961;43:722-733.
3. Kenwright J, Taylor RG. Major injuries of the talus. *J Bone Joint Surg Br* 1970;52:36-48.
4. Eichenholtz SN, Levine DB. Fractures of the tarsal navicular bone. *Clin Orthop Relat Res* 1964;34:142-57.
5. Main BJ, Jowett RL. Injuries of the midtarsal joint. *J Bone Joint Surg Br.* 1975;57:89-97.
6. Kelikian A. *Operative Treatment of the Foot and Ankle.* Appleton and Lange. 1999.
7. Hansen ST. *Functional Reconstruction of the Foot and Ankle.* Lippincott Williams & Wilkins. 2000.
8. Pinney SJ, Sangeorzan BJ. Fractures of the tarsal bones. *Orthop Clin North Am.* 2001;32:21-33.
9. Klaue K. Chopart fractures. *Injury* 2004;35 Suppl 2:SB64-70.
10. Swords MP, Schramski M, Switzer K, Nemeč S. Chopart fractures and dislocations. *Foot Ankle Clin* 2008;13:679-93.
11. Ly TV, Coetzee JC. Treatment of primarily ligamentous Lisfranc joint injuries: primary arthrodesis compared with open reduction and internal fixation. A prospective, randomized study. *J Bone Joint Surg Am* 2006;88:514-20.
12. Rammelt S, Schneiders W, Schikore H, Holch M, Heineck J, Zwipp H. Primary open reduction and fixation compared with delayed corrective arthrodesis in the treatment of tarsometatarsal (Lisfranc) fracture dislocation. *J Bone Joint Surg Br* 2008;90:1499-506.
13. Henning JA, Jones CB, Sietsema DL, Bohay DR, Anderson JG. Open reduction internal fixation versus primary arthrodesis for lisfranc injuries: a prospective randomized study. *Foot Ankle Int* 2009;30:913-22.
14. Sheibani-Rad S, Coetzee JC, Giveans MR, DiGiovanni C. Arthrodesis versus ORIF for Lisfranc fractures. *Orthopedics* 2012;35:e868-73. doi: 10.3928/01477447-20120525-26.

Consensus session 4: Ankle Instability

Chairman: Nick Geary

(Note: where the speaker expresses a personal opinion or preference this is highlighted in italics to distinguish from consensus statements.)

Ankle ligamentous injuries are amongst the most common types of injury sustained during sporting activities. The majority of these injuries involve the lateral ligamentous complex, which consists of the anterior talofibular ligament (ATFL), the calcaneofibular ligament (CFL), and the posterior talofibular ligament (PTFL). The ATFL is the most frequently injured ligament.

Conservative Management of Ankle Instability - Mark Herron

Chronic ankle instability is the persistence of mechanical and functional instability. Mechanical instability presents as recurrent episodes of instability with documented pathological laxity after an ankle ligament injury. Functional instability presents as recurrent episodes of ankle instability and sensation of insecurity or apprehension in the ankle joint due to proprioceptive and neuromuscular deficits, sometimes in the absence of demonstrable ankle laxity or mechanical instability. Hertel recognised that chronic ankle instability can arise from an interplay between mechanical and functional insufficiencies (Figure 1).¹

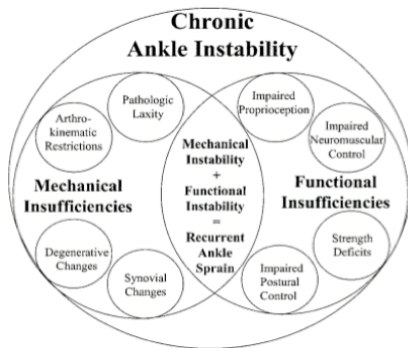


Figure 1. The interplay between mechanical and functional insufficiencies in chronic ankle instability.

The mainstay of conservative management of ankle instability centres on addressing functional insufficiencies arising from **proprioceptive and neuromuscular problems**. Proprioceptive problems include damage to the mechanoreceptors in the joint capsule, damage to peroneal muscle spindle cells, and damage to cutaneous sensation of the foot from soft tissue injury. Neuromuscular problems include peroneal muscle weakness or damage, weakness to ankle extensor muscles and problems arising from the central nervous system.

The majority of patients treated with neuromuscular proprioceptive rehabilitation programmes will improve and approximately 20% will continue to have ongoing symptoms.^{2,3,4} It is unclear how many patients with chronic ankle instability go on to develop ankle osteoarthritis, with conflicting reports in the literature.^{5,6}

Proprioceptive training (e.g. wobble boards), and neuromuscular exercise (e.g. strengthening peroneal muscle complex), are the mainstay of physiotherapy treatment.^{7,8,9,10,11} Lack of a universally accepted definition for chronic ankle instability, significant variation in treatment protocols and the use of a variety of different outcome measures make review of the literature difficult. A systematic review by McKeon found that completing at least 6 weeks of balance training after an acute ankle sprain substantially reduced the risk of recurrent ankle sprains.¹² A Cochrane review in 2011 found only 4 suitable randomised controlled trials using neuromuscular rehabilitation programmes of 4 to 6 weeks duration that showed a small short-term improvement in recurrent instability.¹³

Ankle braces are also used ranging from rigid, semi-rigid and soft braces with one study suggesting a semi-rigid brace to be most effective in controlling ankle inversion.¹⁴ There are conflicting reports in the literature regarding the effectiveness of bracing, and the decision to use an ankle brace is largely patient dependent.

Ankle taping probably contributes to mechanical limitation of movement, joint stabilisation, and improved proprioception. A literature review by Verhagen et al found that ankle taping, bracing and neuromuscular training were all effective in reducing the incidence of ankle sprain recurrences in a proportion of patients.¹⁵

Surgical Role for Acute Ligamentous Injury - Rhys Thomas

The majority of acute ligamentous ankle injuries affect the lateral ligamentous complex. In the general population, patients with acute ankle sprains do well with **functional rehabilitation**, with a small proportion experiencing ongoing symptoms. In the high demand athlete, accelerated rehabilitation, an objectively stable ankle, and an early return to sporting activity are often the priorities. This must be balanced by the need to **avoid chronic problems of pain, swelling and recurrent instability**. Surgery may be an advantage if it decreases recurrent ankle sprains, avoids chronic problems, and confers subjective and objective ankle stability.

A Cochrane review in 2007 found no difference in outcome in surgical versus conservative treatment for acute injuries of the lateral ligament complex of the ankle in adults.⁴ A randomized controlled trial of surgical versus functional treatment for acute grade III injuries found no significant difference in ankle scores and no difference in stress radiographs between the two groups. The non-surgical group had a higher re-injury rate with a risk difference of 32%. There was a higher rate of grade II osteoarthritis (27% risk difference) in the ankles treated surgically.¹⁶ A cohort study by Takao et al found no difference in ankle scores and stress radiographs when comparing groups of patients managed with nonoperative functional treatment alone versus functional treatment after primary surgical repair.¹⁷ There was no significant difference between the two groups in terms of ankle

scores or stress radiographs. However there was a significant decrease in instability in the surgical group, and a significant decrease in time to return to full athletic activity in the surgical group. A systematic review by Peterson et al concluded that the **majority of lateral ankle ligament injuries could be managed non-operatively**.

The main advantages to acute surgical ligament repair were that **objective instability and recurrence rates were less common** when compared with non-operative treatment.¹⁸ An ESSKA-AFAS consensus meeting in 2011 supported the view that future clinical studies should compare surgical results in experienced hands with the results of functional rehabilitation.

Rehabilitation following surgical repair is divided into 5 stages:

Stage 1 involves surgical recovery and early motion.

Stage 2 involves establishing ankle joint control, improving strength and neuromuscular training.

Stage 3 involves proprioceptive exercises.

Stage 4 involves a step-wise progression of increasing function.

Stage 5 involves sports-specific activity with at least 2 weeks of contact training before return to sport.

The speaker's preference is to rely almost solely on clinical assessment of instability supplemented by an examination under anaesthetic before surgery. A direct repair is performed, with suture anchor augmentation if there is an element of bony avulsion. An ankle arthroscopy is usually performed prior to surgical repair to assess for chondral injuries.

Ankle Instability: Failed Surgery; What next? - Nick Geary

Ankle instability can arise from a number of different conditions. They include lateral ankle ligament failure, medial ankle ligament failure, lateral subtalar ligament failure, osteochondral defects of the talus, peroneal tendon dislocation, and anteroinferior tibiofibular ligament failure.

The subtalar joint is an S shaped joint that pivots around an axis with an average angle of inclination of 42° relative to the horizontal plane (Figure1). The head of the talus is roughly 16° internally rotated with respect to the calcaneum. Subtalar joint motion therefore occurs in inversion and eversion, and also demonstrates linear motion (anteroposterior movement), like a spiral screw moving forwards in inversion and backwards in eversion. The variable axis of the subtalar joint is mirrored by the axis of the calcaneofibular ligament. The ATFL prevents anterior subluxation and stops the CFL from swinging too far anteriorly in an arc at heelstrike (Figure 2). The ATFL is tight in plantarflexion and the CFL is tight in dorsiflexion.

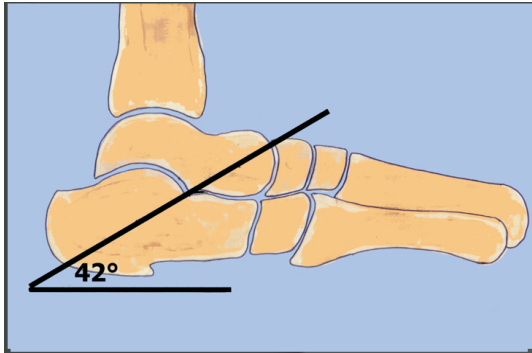


Figure 1. Subtalar joint

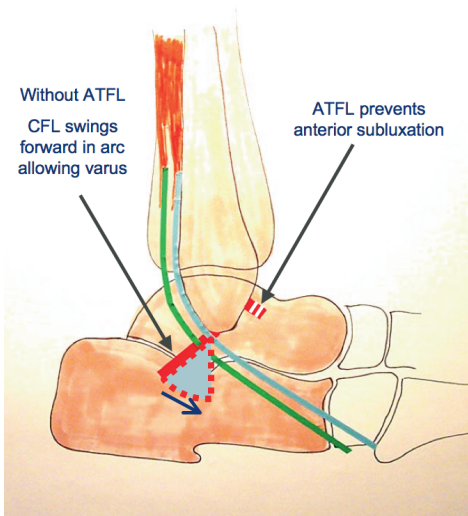


Figure 2. ATFL and CFL in relation to the subtalar joint

The requirements for surgical success in addressing ankle instability are as follows:

1. Both the ATFL and CFL must be stable
2. CFL repair must be parallel with the subtalar joint axis
3. No part of the repair should restrict subtalar joint motion
4. Any underlying predisposing causes should be addressed

The **anatomical repair** e.g. the modified Broström repair produces a more stable repair compared to **non-anatomical** tenodesis procedures e.g. the Chrisman-Snook, and Watson-Jones procedure.¹⁹

Tenodesis procedures involve a segment of tendon crossing the subtalar joint hence limiting motion. The anatomical modified Broström repair reproduces a more normal ligament strain.²⁰

NG prefers to perform an MRI and a staged ankle arthroscopy before ligament repair. The goals of arthroscopy are to remove synovitis, anterior exostosis, and to treat any associated osteochondral lesions of the talus. Stress radiographs, though useful, can be misleading. NG routinely performs an examination under anaesthetic. He is prepared to explore clinically persistent unstable ankles, sometimes in the presence of normal stress examinations, in the belief that poor ligamentous attachments can also be painful.

Direct repair e.g. the modified Broström–Gould technique is optimal as it avoids donor morbidity and probably gives better proprioception. He does not tend to use suture anchors because of the desire to spread the ligament repair out across its anatomical attachment (Figure 3). One of the perceived disadvantages of suture anchors is the resultant bunching up of the ligament repair to a single point. The repair is performed through multiple K wire holes in the fibula that gives a more even attachment. The ATFL and CFL repairs are tensioned separately. Small bony avulsions can result in non-union and these loose fragments of bone attached to intact lateral ligaments can produce pain. These bony fragments are removed and the lateral ligaments are repaired back to bone.

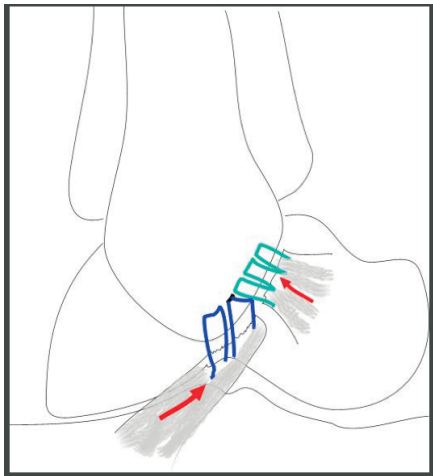


Figure 3. Broström – Gould technique tips. Suturing through multiple k wire holes gives more even attachment than anchors. Insert and tighten sutures to tension ATFL and CFL separately.

If it is not possible to repair the lateral ligaments, then reconstruction options should be considered. The Watson-Jones, Evan's, Larsen and Chrisman-Snook procedures all involve a segment of tendon graft crossing the subtalar joint perpendicular to the axis of motion and therefore restricting subtalar joint motion.

In situations of failed surgery, management strategies depend on the problem. Problem types can be divided into unstable, stable and painful, degenerative and stiff painful ankles. In situations of recurrent instability where the previous repair was insufficient, it is possible to redo the repair with the option of using free graft.

If a modified Broström–Gould repair is not possible, NG uses a 50% strip of free peroneus brevis graft and reconstructs both ATFL and CFL ligaments in its anatomical positions through bony drill holes. A “hockey stick” incision posterior to the lateral malleolus is preferred, to enable access for peroneus brevis tendon graft harvest (Figure 4).

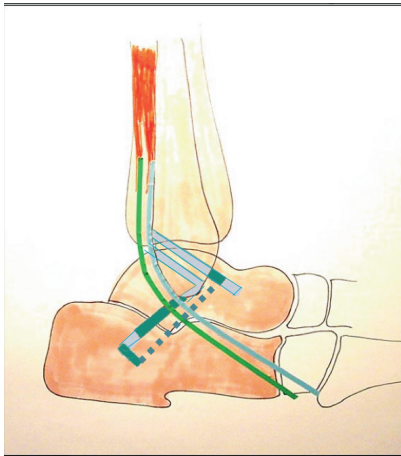


Figure 4. Anatomical reconstruction using autograft. Tendon graft is passed through drill holes to reconstruct ATFL and CFL.

Recurrent instability where the previous operation involved older non-anatomical procedures e.g. Chrisman-Snook or Watson-Jones procedures, can be revised by re-routing the graft or using free tendon graft in more anatomical positions. Underlying problems such as a cavovarus deformity should be corrected otherwise any ligament repair or reconstruction is likely to fail.

Stable but painful ankles should be managed by treating associated causes such as loose bodies, osteochondral lesions, anterior or posterior impingement, and degenerative joint disease. Pain may also arise from adjacent subtalar or talonavicular joints and it may be necessary to fuse these degenerative painful joints. Consider other causes of instability such as Charcot neuroarthropathy, pes planus, and subtalar coalitions.

In severe degenerative ankles, the management will be either an ankle fusion or ankle replacement. Consider an ankle fusion in younger patients and in cases where there is malleolar malposition and severe malalignment. Consider an ankle replacement in patients who have polyarthropathy, subtalar degeneration and good overall alignment.

In stiff and painful ankles, the management should involve an arthroscopic synovectomy. Radiofrequency probes are not advised in the ankle due to capsular shrinkage and resultant stiffness. Lesions causing impingement should also be addressed. Ultimately patients may require an arthroscopic fusion. Long-term splintage may be the only option in patients who are unfit for surgery.

In summary, the management of problematic ankle instability should involve:

1. Ensuring an anatomical repair or reconstruction
2. Treating associated problems such as osteochondral lesions, impingement, and peroneal tendon dislocation
3. Ensuring that the correct joint is identified and treated
4. Treating arthritis with either a fusion or replacement

Consensus statements for Chronic Ankle Instability

There was consensus that there should be no age cut off for surgery (100%), and that the decision should be based on a patient's physiological status (92%).

There was a split of opinion that stress views were necessary (50%/50%). If stress views were performed there was consensus that it should involve bilateral views (70%), and be performed under general anaesthetic (70%).

There was consensus that an MRI scan should be performed before surgery (88%).

There was consensus that an ankle arthroscopy should be performed (70%), and that it should be performed as a single stage procedure at the same time as ligament repair or reconstruction surgery (always =62% or sometimes =24%). A small number of surgeons exclusively performed this as a two-staged procedure (14%).

There was consensus that the CFL should be examined at the time of surgery (79%).

There was a split of opinion regarding the type of incision: Broström – anterior to the fibula (30%), "Hockey Stick" – posterior to the fibula (20%) and middle of the fibula (35%).

There was consensus that the initial revision operation for a failed Broström repair was a re-do modified Broström repair (70%). A small number of surgeons perform a tendon autograft reconstruction as the initial revision operation (15%).

In surgery involving a modified Broström repair with a valgus calcaneal osteotomy, there was a split of opinion regarding the number of incisions with two incisions (35%), one incision (30%) and Minimally Invasive Surgery (20%).

In hypermobility syndromes, if all non-operative measures were exhausted, there was a split of opinion regarding the choice of primary surgery that included modified Broström repair (15%), tendon autograft (32%) and synthetic graft (6%). Tendons harvested included Peroneus Brevis (41%) and hamstrings (26%).

References

1. Hertel J. Functional Anatomy, Pathomechanics, and Pathophysiology of Lateral Ankle Instability. *J Athl Train* 2002;37:364-375.
2. van Rijn RM, van Os AG, Bernsen RM, Luijsterburg PA, Koes BW, Bierma-Zeinstra SM. What is the clinical course of acute ankle sprains? A systematic literature review. *Am J Med*. 2008;121:324-331.e6.
3. Hupperets MD, Verhagen EA, Heymans MW, Bosmans JE, van Tulder MW, van Mechelen W. Potential savings of a program to prevent ankle sprain recurrence: economic evaluation of a randomized controlled trial. *Am J Sports Med* 2010;38:2194-200.
4. Kerkhoffs GM, Handoll HH, de Bie R, Rowe BH, Struijs PA. Surgical versus conservative treatment for acute injuries of the lateral ligament complex of the ankle in adults. *Cochrane Database Syst Rev*. 2007 Apr 18;(2):CD000380.
5. Harrington KD. Degenerative arthritis of the ankle secondary to long-standing lateral ligament instability. *J Bone Joint Surg Am* 1979;61:354-61.
6. Löfvenberg R, Kärrholm J, Lund B. The outcome of nonoperated patients with chronic lateral instability of the ankle: a 20-year follow-up study. *Foot Ankle Int* 1994;15:165-9.
7. Osborne MD, Chou LS, Laskowski ER, Smith J, Kaufman KR. The effect of ankle disk training on muscle reaction time in subjects with a history of ankle sprain. *Am J Sports Med* 2001;29:627-32.
8. Hughes T, Rochester P. The effects of proprioceptive exercise and taping on proprioception in subjects with functional ankle instability: a review of the literature. *Phys Ther Sport* 2008;9:136-47.
9. Mitchell A, Dyson R, Hale T, Abraham C. Biomechanics of ankle instability. Part 1: Reaction time to simulated ankle sprain. *Med Sci Sports Exerc* 2008;40:1515-21.
10. Postle K, Pak D, Smith TO. Effectiveness of proprioceptive exercises for ankle ligament injury in adults: a systematic literature and meta-analysis. *Man Ther* 2012;17:285-91.
11. Kerkhoffs GM, van den Bekerom M, Elders LA, van Beek PA, Hullegie WA, Bloemers GM, de Heus EM, Loogman MC, Rosenbrand KC, Kuipers T, Hoogstraten JW, Dekker R, Ten Duis HJ, van Dijk CN, van Tulder MW, van der Wees PJ, de Bie RA. Diagnosis, treatment and prevention of ankle sprains: an evidence-based clinical guideline. *Br J Sports Med* 2012;46:854-60.
12. McKeon PO, Hertel J. Systematic review of postural control and lateral ankle instability, part II: is balance training clinically effective? *J Athl Train* 2008;43:305-15.
13. de Vries JS, Krips R, Sierevelt IN, Blankevoort L, van Dijk CN. Interventions for treating chronic ankle instability. *Cochrane Database Syst Rev*. 2011;8:CD004124.
14. Eils E, Demming C, Kollmeier G, Thorwesten L, Völker K, Rosenbaum D. Comprehensive testing of 10 different ankle braces. Evaluation of passive and rapidly induced stability in subjects with chronic ankle instability. *Clin Biomech* 2002;17:526-35.

15. Verhagen EA, Bay K. Optimising ankle sprain prevention: a critical review and practical appraisal of the literature. *Br J Sports Med* 2010;44:1082-8.
16. Pihlajamäki H, Hietaniemi K, Paavola M, Visuri T, Mattila VM. Surgical versus functional treatment for acute ruptures of the lateral ligament complex of the ankle in young men: a randomized controlled trial. *J Bone Joint Surg Am* 2010;92:2367-74.
17. Takao M, Miyamoto W, Matsui K, Sasahara J, Matsushita T. Functional treatment after surgical repair for acute lateral ligament disruption of the ankle in athletes. *Am J Sports Med* 2012;40:447-51.
18. Petersen W, Rembitzki IV, Koppenburg AG, Ellermann A, Liebau C, Brüggemann GP, Best R. Treatment of acute ankle ligament injuries: a systematic review. *Arch Orthop Trauma Surg* 2013;133:1129-41.
19. Liu SH, Baker CL. Comparison of lateral ankle ligamentous reconstruction procedures. *Am J Sports Med* 1994;22:313-7.
20. Bahr R, Pena F, Shine J, Lew WD, Tyrdal S, Engebretsen L. Biomechanics of ankle ligament reconstruction. An in vitro comparison of the Broström repair, Watson-Jones reconstruction, and a new anatomic reconstruction technique. *Am J Sports Med* 1997;25:424-32.

Consensus Session 5: Gastrocnemius Tightness

Chairman: Dishan Singh

Operations for gastrocnemius tightness are being increasingly promoted but the definition, prevalence, pathomechanics, evaluation and treatment of this condition are as yet not fully defined.

(Note: where the speaker expresses a personal opinion or preference this is highlighted in italics to distinguish from consensus statements.)

Assessment of Gastrocnemius Tightness - Robert Clayton

There is no clear agreed definition of gastrocnemius tightness. DiGiovanni et al defined gastrocnemius tightness $\leq 10^\circ$ of dorsiflexion of the ankle when the knee is extended.¹ This degree of contracture however, was found in 44% of asymptomatic patients, possibly limiting the clinical value of such a definition.

The importance of the gastrocnemius muscle lies in the fact that it crosses three joints, the knee, ankle and subtalar joint. **Ensuring that the subtalar joint is in neutral** is important when assessing gastrocnemius tightness. The gastrocnemius muscle originates above the knee, and the soleus muscle originates below the knee on the posterior aspect of the proximal tibia. Hence, when the knee is flexed, gastrocnemius is relaxed, and anything that restricts motion at the ankle is either due to intrinsic problems at the ankle, or to contractures of the soleus muscle. In knee extension, the gastrocnemius muscle is under tension. If there is a difference in the range of dorsiflexion of the ankle when the knee is flexed compared to when the knee is extended, the difference can be attributed to gastrocnemius tightness.

Silfverskiöld originally described his test in neuromuscular conditions in children such as cerebral palsy.² The test is now commonly performed by assessing passive range of dorsiflexion at the ankle. With the knee fully flexed, the range of dorsiflexion at the ankle is assessed. This is then compared with the range of dorsiflexion at the ankle with the knee fully extended.

A variety of conditions affecting the foot and ankle have been associated with gastrocnemius tightness. In the case of forefoot pain, on standing with the knee extended, gastrocnemius tightness causes a disproportionate amount of force to be concentrated in the forefoot. DiGiovanni et al found gastrocnemius tightness in up to 88% of patients with **metatarsalgia**, probably due to mechanical overload.¹ There is a link between gastrocnemius tightness, **forefoot overload and interdigital neuroma**. The link between hallux valgus and gastrocnemius tightness is controversial. Overload of the forefoot as a result of gastrocnemius tightness is thought to increase stress on the plantar plate and lead to lesser toe deformities. **In diabetic feet, forefoot overload can lead to ulceration**. There is also a link between gastrocnemius contractures and planovalgus deformities, although the exact cause-effect relationship has not been firmly established.³

Tightness of the Achilles tendon can predispose to **plantar fasciitis** because limited dorsiflexion of the foot strains the plantar fascia.^{4,5} Patel and DiGiovanni found that up to 57% of patients with plantar fasciitis have gastrocnemius contractures.⁵ The Surrey group have reported good results with proximal medial gastrocnemius release in the treatment of recalcitrant plantar fasciitis: 17 out of 21 heels reported total or significant pain relief following gastrocnemius release.⁶

There is an association between gastrocnemius tightness and **tendoachilles pathology**, which may also explain why stretching exercises improve symptoms. The Surrey group reported on a small series of patients who had gastrocnemius releases for Achilles tendinopathy and found that 6 out of 9 patients were highly satisfied with the results of surgery.⁷

RC routinely assesses gastrocnemius tightness in the outpatient setting only in conditions where it would affect management. These conditions include presentations for forefoot pain, flatfoot, cavus foot, plantar fasciitis and Achilles tendon pain. In the case of total ankle replacements and flatfoot reconstructions, a decision on whether to perform a gastrocnemius release or recession is made intraoperatively.

Conservative Treatment - Gary Colleary

It is important to distinguish between the following terms used in the literature: **stiffness** i.e. stiffness in the ankle joint; **tightness** i.e. tightness in the muscle complex; and **flexibility** i.e. passive or active flexibility which will determine the treatment.

Stiffness in the ankle joint can be due to conditions affecting muscle or connective tissue. Connective tissue responds to stretching over a period of time where the collagen fibres align along the line of force. Hence stretching connective tissue is a long term, progressive exercise. In tight muscle, a certain percentage of muscle fibres will respond to stretching by elongating fully, resulting in progressive lengthening. However, when stretching stops the muscle fibres tend to contract again.

Flexibility can be divided into dynamic, static-active and static-passive flexibility. Dynamic flexibility refers to normal movement. Static-active flexibility is the action of maintaining a limb position in space using agonist and synergist muscles. Static-passive flexibility is the action of assuming an extended position e.g. touching toes or pushing against a wall.

Static-passive stretching does stretch the gastrocnemius complex, but research suggests that static-passive programmes improves passive but not active flexibility. In stretching, the muscles lengthen by reducing myofilament overlap, and the number of fibres that are stretched governs the overall length of the muscle. Prolonged stretching is necessary to ensure maximal lengthening, and if stretching stops the lengthening achieved can regress.

The different conservative treatments identified in the literature are stretching, casting, splintage, massage and electrical stimulation. **Stretching is the predominant modality of treatment.** Ballistic stretches are 'bouncing' stretches that can lead to injury in the non-athletic population. Dynamic stretches involve controlled movement. Active stretching involves maintaining position of the limb

using agonist and synergist muscles; and passive stretching involves stretching by resting the limb against a fixed object that supports the stretching. Isometric stretching is static stretching against resistance, which involves muscle contraction to reduce the myofibril overlap. Proprioceptive Neuromuscular Facilitation (PNF) stretching e.g. Thera-Band in stretching, is used clinically to enhance both active and passive range of motion to optimise motor performance and rehabilitation.

The literature on stretching mainly relates to conditions such as **plantar fasciitis and achilles tendinopathy** e.g. eccentric stretching or plantar fascial stretching. A meta-analysis by Radford et al found that stretching for 15-30 minutes a day does lead to a small increase in range of ankle dorsiflexion. However, it is unclear whether the change is clinically important.⁸

The other treatments mentioned above: casting, splintage, massage and electrical stimulation have very little evidence to support its use in isolation. They are often used in combination with stretching exercises for maximal efficacy.

In conclusion, stretching should be tailored to the relevant activity e.g. if the gastrocnemius tightness is affecting gait then dynamic stretching would be indicated. Stretching can improve the range of dorsiflexion. In conditions where symptoms are attributable to gastrocnemius tightness, treatment should be focused on treating gastrocnemius tightness rather than on treating symptoms alone.

Surgical Treatment - Strayer/Vulpus/Baker/Endoscopic Technique - Judith Baumhauer

What is the definition of gastrocnemius contracture?

A suggested definition of gastrocnemius contracture is $\leq 10^\circ$ of ankle dorsiflexion with knee extended that improves past neutral with knee flexed.^{1,5}

How often does a contracture occur?

65-88% patients with midfoot or forefoot symptoms vs 25% in asymptomatic controls.¹
57% patients presenting with foot pain have gastrocnemius contracture.⁵

How much Ankle Dorsiflexion is needed for normal walking gait?

10-18° of ankle dorsiflexion is needed for normal gait.¹⁰

The different techniques described differ according to the level where the gastrocnemius recession or release is performed (figure 1):

The posterior side of the limb can be divided into five levels based on anatomic landmarks. Each anatomic level corresponds to a specific operative release of the gastrocnemius-soleus complex. GT, gastrocnemius tenotomy; GSR, gastrocnemius-soleus recession; TAL, Achilles tendon lengthening.

(From: Herzenberg JE, Lamm BM, Corwin C, Sekel J. Isolated recession of the gastrocnemius muscle: the Baumann procedure. Foot Ankle Int. 2007 Nov;28(11):1154-9)

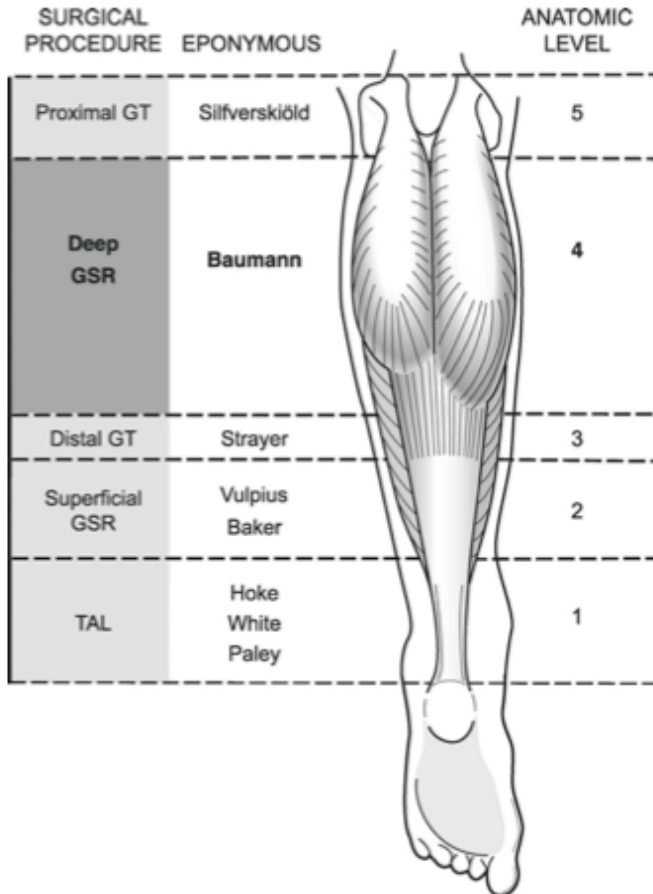


Figure 1. Types of gastrocnemius release by location.⁹

The Vulpius technique involves an incision at the distal 1/3rd of soleus muscle. The superficial gastrocnemius fascia, deep soleus fascia and median raphe of the soleus muscle are divided transversely.¹¹

The Strayer technique involves a distal gastrocnemius tenotomy just proximal to the gastrocnemius-soleus aponeurosis. The fascia is cut 1-2cm distal to the muscle belly, dividing only the gastrocnemius fascia, leaving the soleus intact. The original description involved a release and re-suture to the soleus fascia.¹²

What strength implications does a gastrocnemius recession have?

Sammarco et al performed isokinetic strength tests in patients with a unilateral gastrocnemius recession. They found that the peak torque recovery after a (Vulpus) gastrocnemius recession showed almost a 20% deficit at 18 months compared to the contralateral extremity.¹³

What improvement in range of motion is achieved after a gastrocnemius recession?

Pinney et al found that following a Strayer procedure there was an 18.1° improvement in ankle dorsiflexion at an average follow up of 55 days. It is unclear if this improvement is maintained long term.¹⁴

What are the outcomes of gastrocnemius recession?

On the whole, patients are satisfied with results following a gastrocnemius recession. Figure 2 summarises some of the published results of gastrocnemius recession.

Procedure	Indication	Outcome	Author
Strayer	NI Achilles tendonitis	Improved AOFAS Improved FFI Increased DF (13°) 92% sat	Duthon 2011
Strayer	PF; metatarsalgia ; arch pain	VAS pain improvement; 93% patient sat.	Maskill 2010
Strayer	PF	Improved FAAM; increased ROM (14°); increased strength?	Chimera 2010
Strayer	Metatarsagia ; PF; Bunion ; PTTD	18.1° increase in DF	Pinney 2002
Vulpus	Ins. AT; NI AT	Improved pain VAS	Laborde 2011
Endoscopic	Ulcer; Bunion ; Flatfoot ; Charcot ; CMT ; midfoot arthritis	Decreased pain; stiffness; Improved Olerud and Molander score	Trevino 2005

Figure 2. Published results of gastrocnemius recession

What are the complications of gastrocnemius recession?¹⁵⁻²¹

Sural nerve injury

open(2%)

endoscopic (16%)

Infection

Wound healing

Prolonged weakness

CRPS

In summary gastrocnemius recession appears to improve range of motion, weakens the muscle for the first 1-2 years after which its effect is unknown. It is associated with low risks, and improves pain in some foot and ankle pathology. More evidence is needed to evaluate its efficacy.

JB performs gastrocnemius recession for midfoot arthritis, forefoot metatarsalgia, plantar fasciitis, and insertional and non-insertional Achilles tendinopathy. She allows her patients to fully mobilise one week post-operatively.

Proximal Medial Gastrocnemius Release - Derek Park

The **proximal medial gastrocnemius release** is done at the level between the Baumann and Silfverskiöld procedures (Figure1). In a textbook on gastrocnemius tightness, Samuel Barouk described his experience with gastrocnemius release by sectioning the white fibres of the medial and lateral gastrocnemius muscles proximally.²² Colombier, Toullec, Samuel and Pierre Barouk subsequently modified their technique to perform a release of only the medial gastrocnemius muscle.²³

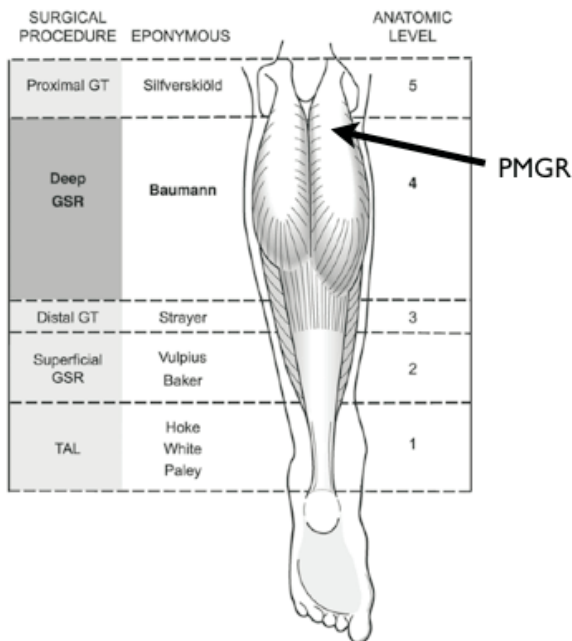


Figure 1. Level of PMGR

The Surrey group published a cadaveric study looking at the approach to the medial and lateral heads of the Gastrocnemius.²⁴ They found that the approach to the medial head was far less likely to cause cutaneous nerve damage compared to the lateral approach. Fifteen cadaveric knee specimens were examined and the position of the nerves in relation to the midline of the lower leg were documented. On the medial side the superficial dissection was free from nervous structures. On the lateral side, the medial sural cutaneous and lateral sural cutaneous nerves were identified and were always deep to the fascia. They also found that on average the cross sectional area of the medial Gastrocnemius aponeurosis was 2.4x larger than the lateral head, possibly explaining why isolated medial head release is so effective.

The proximal medial gastrocnemius release (PMGR) is commonly used in **conjunction with eccentric stretching exercises** and other modalities of treatment in the management of **recalcitrant plantar fasciitis and Achilles tendon disorders**. Patients are only offered surgical treatment if they have failed conservative treatment with supervised physiotherapy.

The following is a summary of the Surrey (Matthew Solan) experience of the technique of PMGR: *Almost all patients are done under local anaesthetic and conscious sedation using propofol or midazolam administered by the anaesthetist. Local infiltration is performed with 20mls of 1% Xylocaine with adrenaline. The patient is positioned prone and local anaesthetic is infiltrated before sterile preparation and draping of the patient. The needle is advanced and it is important to infiltrate local anaesthetic deep to fascia. The medial dimple of the popliteal fossa is located and the horizontal incision is marked 2 cm distal and lateral to it. (figure 2)*

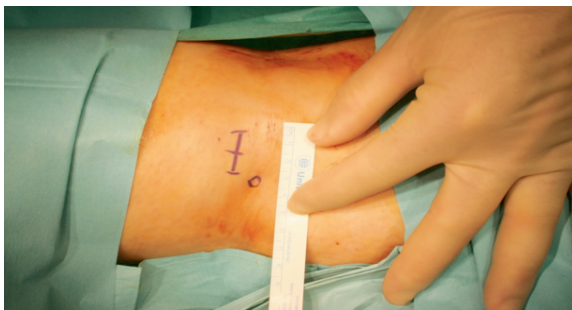

Figure 2. Incision for PMGR (left leg). The medial fossa is marked with a circle. (With thanks to Matthew Solan for providing this intraoperative photograph)

The medial dimple represents the boundary of the dissection and it is important to keep the incision lateral to avoid injury to the branches of saphenous nerve or vein. A small incision is made through the skin and the subcutaneous fat. The incision is then deepened through the deep fascia to expose the underlying aponeurosis of the medial head of the gastrocnemius. The aponeurosis is then divided with scissors, ensuring a semi-circumferential release to the anterior aspect of the medial head. The skin is closed using absorbable sutures. A small adhesive dressing is applied. Patients did not require a cast or brace and should continue with their eccentric calf stretches, going back to normal activities in 2 weeks.

In a series from the Surrey group published in Foot and Ankle International, 21 cases of recalcitrant plantar fasciitis were followed up at an average of 24 months. Outcome measures used were the 5-point Likert scale and assessment of calf weakness. The majority of patients were either significantly improved or pain free, with 88% saying they would recommend their surgery to others.⁶

The Surrey group also reported on the effects of PMGR in Achilles tendinopathy in 10 cases with a minimum follow up of 18 months. They looked at the Visual analogue scale, VISA-A, AOFAS ankle-hindfoot score and overall satisfaction score. They generally found high overall satisfaction, and statistically significant improvement across all outcome measures in the non-insertional Achilles tendinopathy group.⁷

In conclusion the proximal medial gastrocnemius release is used in the management of patients with **gastrocnemius tightness and recalcitrant plantar fasciitis or Achilles tendinopathy**. The operation can be done as a daycase procedure under LA +/- sedation, enables early rehabilitation and is associated with few complications.

Consensus statements for Gastrocnemius Tightness/Contracture

Number of gastrocnemius lengthening procedures performed annually:

- 0-5 cases (20%)
- 6-10 cases (35%)
- 11-20 cases (35%)
- >20 cases (10%)

What is your default procedure for gastrocnemius lengthening?

- Medial head (26%)
- Medial + lateral heads (0%)
- Baumann (0%)
- Open Strayer / Vulpius (64%)
- Endoscopic (5%)
- Speculum (5%)

There was consensus (>75%) that the Silfverskiöld test, in patients with a flat foot or cavus foot, should be done with the talonavicular joint in neutral. The results of the voting were:

When you do a Silfverskiöld test on a patient with a **flat foot**, in which position do you put the subtalar joint?

- Talonavicular joint neutral (76%)
- Full inversion (24%)
- Full eversion (0%)

When you do a Silfverskiöld test on a patient with a **cavus foot**, in which position do you put the subtalar joint?

- Talonavicular joint neutral (81%)
- Full inversion (14%)
- Full eversion (5%)

There was consensus (100%) that the range of dorsiflexion achieved with the Silfverskiöld test is assessed clinically/visually, with no one using a goniometer or equinometer.

There was consensus (100%) that the Silfverskiöld test should assess range of motion in both the knee flexed and knee extended position.

There was consensus (78%) that an acceptable definition of gastrocnemius contracture was $\leq 10^\circ$ of dorsiflexion of the ankle when the knee is extended.

References

1. DiGiovanni CW, Kuo R, Tejwani N, Price R, Hansen ST Jr, Cziernecki J, Sangeorzan BJ. Isolated gastrocnemius tightness. *J Bone Joint Surg Am* 2002;84-A:962-70.
2. Silfverskiöld N: Reduction of the uncrossed two-joint muscles of the leg to one-joint muscles in spastic conditions. *Acta Chir Scand* 1924;56:315-330.
3. Arangio G, Rogman A, Reed JF 3rd. Hindfoot alignment valgus moment arm increases in adult flatfoot with Achilles tendon contracture. *Foot Ankle Int* 2009;30:1078-82.
4. Singh D, Angel J, Bentley G, Trevino SG. Fortnightly review. Plantar fasciitis. *BMJ* 1997;315:172-5.
5. Patel A, DiGiovanni B. Association between plantar fasciitis and isolated contracture of the gastrocnemius. *Foot Ankle Int* 2011;32:5-8.
6. Abbassian A, Kohls-Gatzoulis J, Solan MC. Proximal medial gastrocnemius release in the treatment of recalcitrant plantar fasciitis. *Foot Ankle Int* 2012;33:14-9.
7. Gurdezi S, Kohls-Gatzoulis J, Solan MC. Results of proximal medial gastrocnemius release for achilles tendinopathy. *Foot Ankle Int.* 2013 Oct;34(10):1364-9..
8. Radford JA, Burns J, Buchbinder R, Landorf KB, Cook C. Does stretching increase ankle dorsiflexion range of motion? A systematic review. *Br J Sports Med* 2006;40:870-5.
9. Barske HL, DiGiovanni BF, Douglass M, Nawoczenski DA. Current concepts review: isolated gastrocnemius contracture and gastrocnemius recession. *Foot Ankle Int* 2012;33:915-21.
10. Whittle M. *Gait analysis: an introduction*. 2nd ed. Oxford: Butterworth- Heinemann; 1996. p 58.
11. Herzenberg JE, Lamm BM, Corwin C, Sekel J. Isolated recession of the gastrocnemius muscle: the Baumann procedure. *Foot Ankle Int* 2007 Nov;28:1154-9.
12. Strayer, LM Jr: Recession of the gastrocnemius; an operation to relieve spastic contracture of the calf muscles. *J Bone Joint Surg Am.* 1950 Jul;32-A(3):671-6.
13. Sammarco GJ, Bagwe MR, Sammarco VJ, Magur EG. The effects of unilateral gastrocsoleus recession. *Foot Ankle Int* 2006;27:508-11.

14. Pinney SJ, Hansen ST Jr, Sangeorzan BJ. The effect on ankle dorsiflexion of gastrocnemius recession. *Foot Ankle Int* 2002;23:26-9.
15. Saxena A, Widtfeldt A. Endoscopic gastrocnemius recession: preliminary report on 18 cases. *J Foot Ankle Surg* 2004;43:302-6.
16. Trevino S, Gibbs M, Panchbhavi V. Evaluation of results of endoscopic gastrocnemius recession. *Foot Ankle Int* 2005;26:359-64.
17. Rush SM, Ford LA, Hamilton GA. Morbidity associated with high gastrocnemius recession: retrospective review of 126 cases. *J Foot Ankle Surg* 2006;45:156-60.
18. Chen L, Greisberg J. Achilles lengthening procedures. *Foot Ankle Clin* 2009;14:627-37.
19. Duthon VB, Lübbecke A, Duc SR, Stern R, Assal M. Noninsertional Achilles tendinopathy treated with gastrocnemius lengthening. *Foot Ankle Int* 2011;32:375-9.
20. Laborde JM. Neuropathic plantar forefoot ulcers treated with tendon lengthenings. *Foot Ankle Int* 2008;29:378-84.
21. Maskill JD, Bohay DR, Anderson JG. Gastrocnemius recession to treat isolated foot pain. *Foot Ankle Int* 2010;31:19-23.
22. Barouk L.S, Barouk P, editors. *Gastrocnemius Tightness - From anatomy to treatment*. 1st ed. Sauramps Medical; 2013.
23. International meeting of the French Foot societies, Toulouse 2006.
24. Hamilton PD, Brown M, Ferguson N, Adebibe M, Maggs J, Solan M. Surgical anatomy of the proximal release of the gastrocnemius: a cadaveric study. *Foot Ankle Int* 2009;30:1202-6.

Convened participants of the 2013 Round Table Meeting were:

Judith Baumhauer
Harvinder Bedi
Al Best
Maneesh Bhatia
Chris Blundell
Rick Brown
Jim Carmichael
Callum Clark
Robert Clayton
Simon Clint
Tim Clough
Gary Colleary
Paul Cooke
Nick Cullen
Mark Davies
Raman Dega
Sunil Dhar
Nick Geary
Andy Goldberg
Mark Herron
Paul Hodgson
Mike Karski
Senthil Kumar
Derek Park
James Ritchie
Fred Robinson
Mark Rogers
Bob Sharp
Malik Siddique
Dishan Singh
Sam Singh
Rhys Thomas
Ioan Tudur Jones
Alex Wee
Tim Williams
David Williamson



Ortho Solutions Limited
West Station Business Park
Spital Road
Maldon
Essex CM9 6FF
United Kingdom

T: +44 (0) 1621 843599
F: +44 (0) 1621 858953
E: sales@orthosol.com

www.orthosolutions.com